

Feasibility Study for Avoiding or Postponing Biopsy using Improved Imaging: Negative Predictive Value of Micro-Ultrasound for Subjects with Low PSAD

Astobieta A, Sanchez A, De la Cruz I, Pereira JG, Gamarra M, Urdaneta F, Mora G, Ibarluzea G.
Urología Clínica, IMQ, Bilbao, Spain

Introduction & Objectives

Prostate cancer lacks a reliable diagnostic imaging technique, however a novel 29 MHz high resolution micro-ultrasound imaging system with 70 micron resolution appears promising. With the support of the evidence-based **PRI-MUS™** (prostate risk identification using micro-ultrasound) protocol, micro-ultrasound may provide a modality with improved targeting of prostate biopsies, and its improved negative predictive value may reduce over-diagnosis of prostate cancer in men with low risk factors.

Methods:

- This retrospective study includes the first 41 patients undergoing trans-rectal micro-ultrasound guided biopsy using the **ExactVu™** micro-ultrasound system at **IMQ** urology clinic (Bilbao, Spain)
- A standard biopsy protocol (*Figure 3*) was followed, including identifying PRI-MUS scores for each sample. Benign PRI-MUS characteristics followed systematic biopsies and suspicious PRI-MUS scores were targeted. All scores were recorded in the patient file

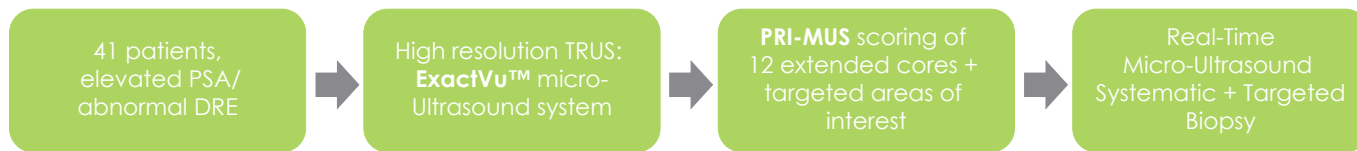

Figure 1: Micro-Ultrasound Study Procedure

- All biopsy samples were obtained under real-time micro-ultrasound guidance
- Negative Predictive Value (NPV) for patients with varying PSAD was evaluated through retrospective analysis

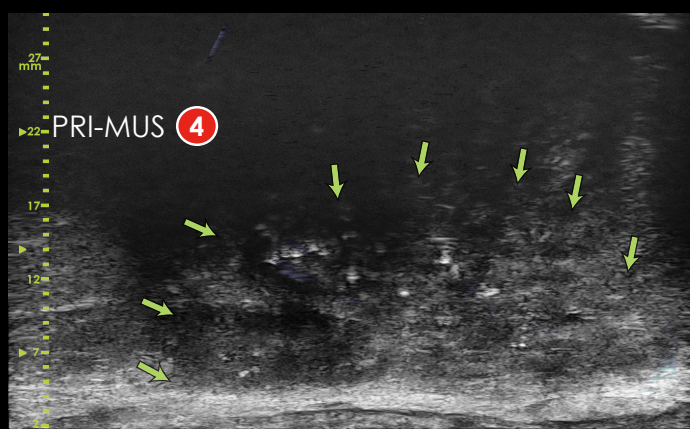


Figure 2: This is a micro-ultrasound image of a patient which was assigned a PRI-MUS 4 score (suspicious target with Cauliflower). This core was shown to be positive on Pathology (Gleason 8). MRI missed that target assigning it with a PI-RADS 2 score

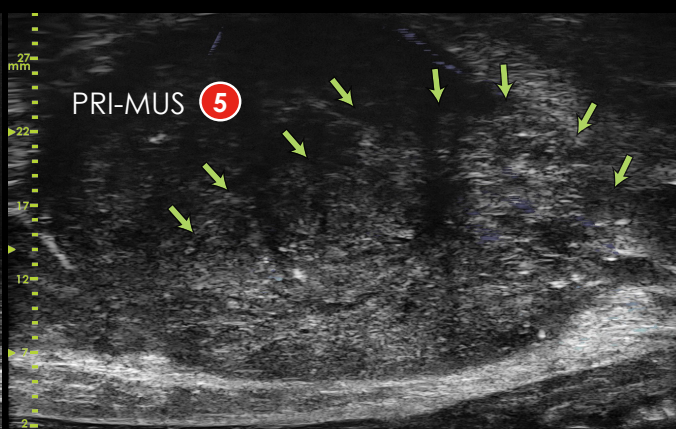


Figure 3: This is a micro-ultrasound image of a patient which was assigned a PRI-MUS 5 score (suspicious target with Irregular Shadowing). This core was shown to be positive on Pathology (Gleason 7). MRI assigned this target a PI-RADS 3 score (equivocal)

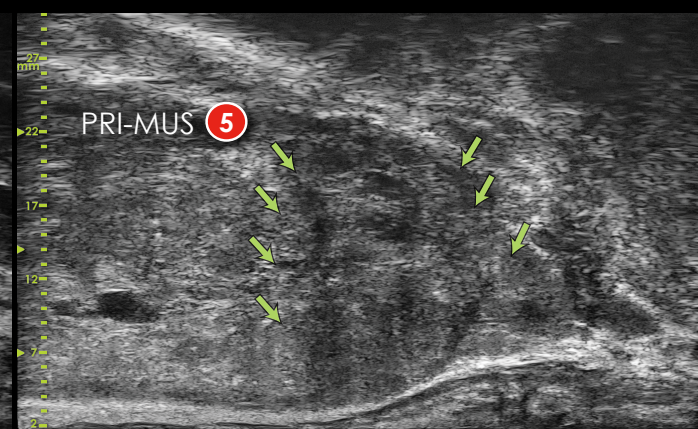

Figure 4: This is a micro-ultrasound image of a patient which was assigned a PRI-MUS 5 score (suspicious target with Irregular Shadowing). This core was shown to be positive on Pathology (Gleason 7). MRI missed that target assigning it with a PI-RADS 2 score

Results:

- Overall NPV at the biopsy sample level was 91.54% in this cohort
- The NPV increased to 94.17% when higher risk subjects (PSAD > 0.25 ng/mL cc, 17/41 subjects) were excluded (*Figure 4*)
- In even lower risk patients with a PSAD < 0.15 ng/mL cc (8/41), the NPV improved slightly to 94.29%

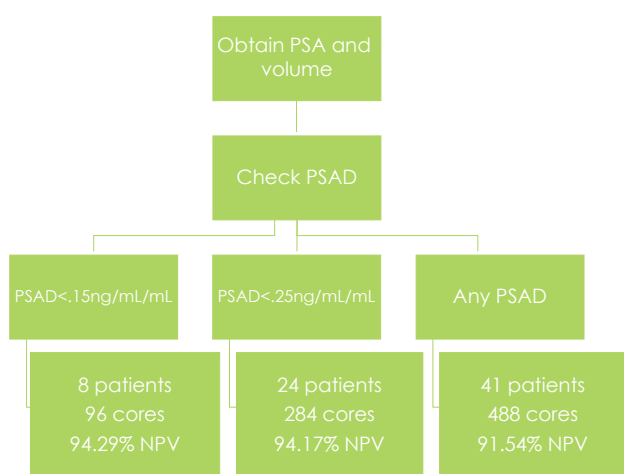


Figure 5: Increase in NPV by filtering low risk patients.

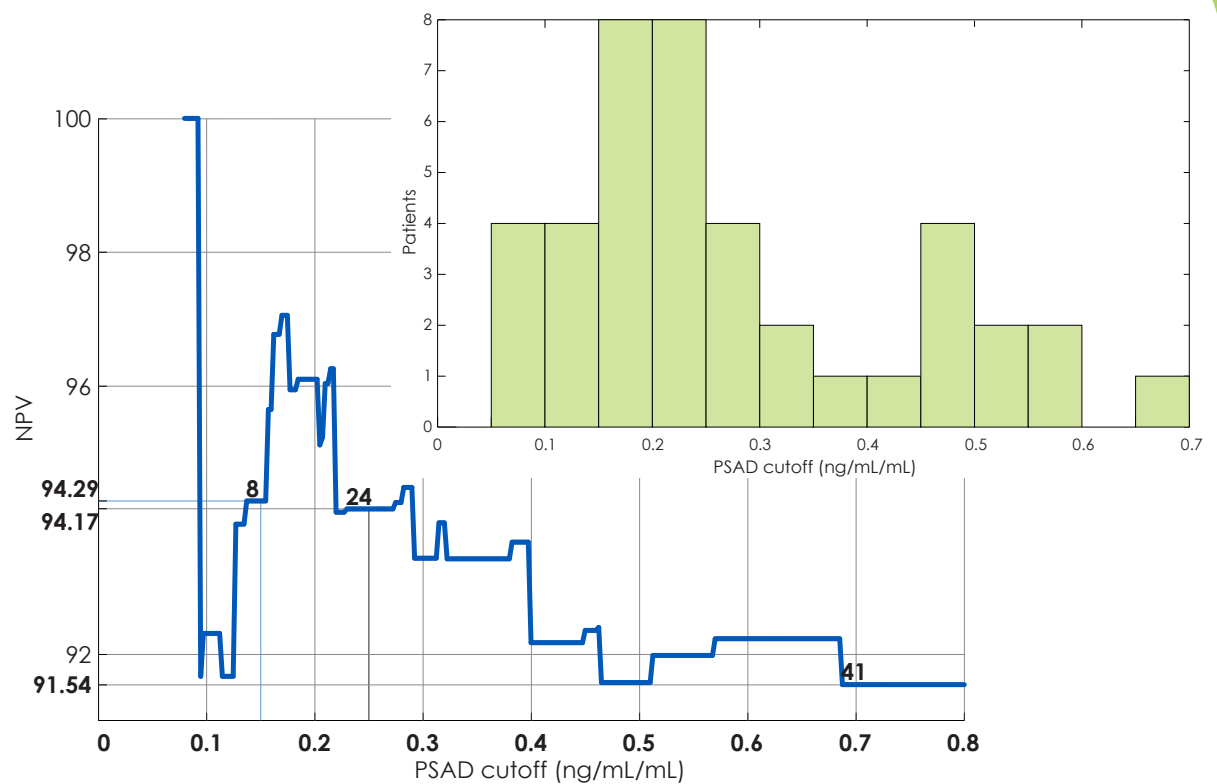


Figure 6: Relationship between PSAD cut-off and NPV using PRI-MUS score. Without any cut-off (including all subjects) a per-zone NPV of 91.5% was achieved, when higher risk patients are removed by applying a PSAD cut-off for targeted-only biopsy, NPV increased to 94%. The histogram (*inset*) shows the range of PSAD values encountered in this cohort, for the loose threshold defined here (0.25ng/mL/cc) 58.5% of subjects would have been eligible for target-only biopsy or biopsy avoidance if no targets were found.

Conclusions

With a negative predictive value of over 94%, micro-ultrasound imaging may be able to safely avoid systematic biopsy in lower risk patients. In this analysis, over 50% of cases could safely have avoided systematic biopsy.